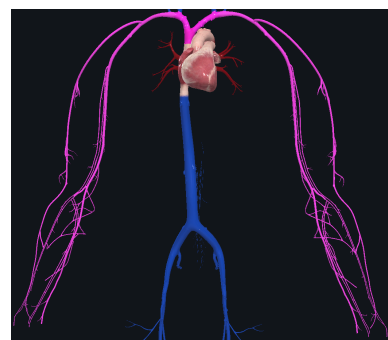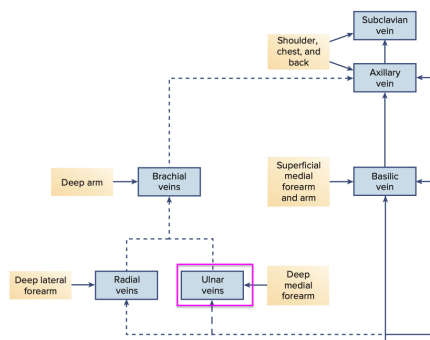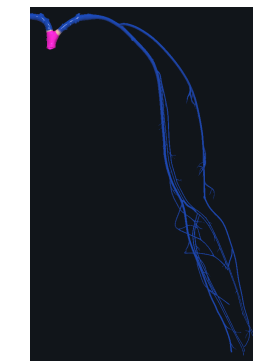
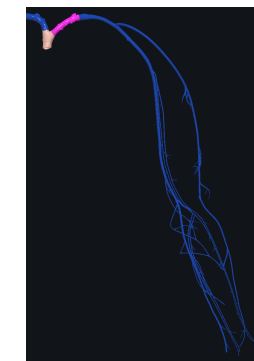
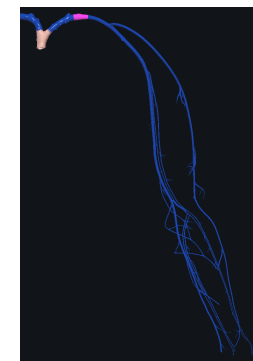
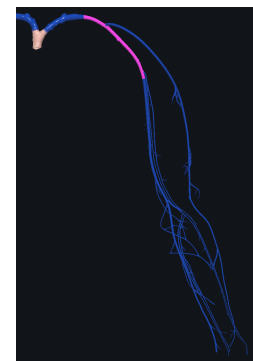
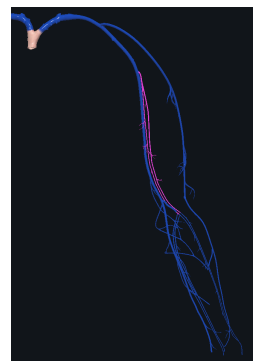
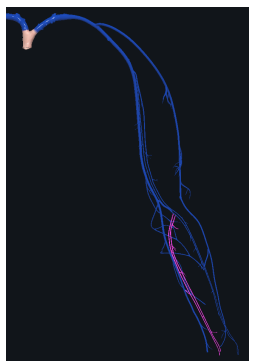
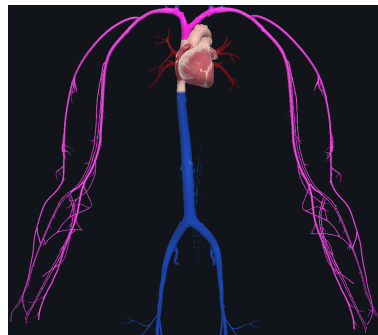
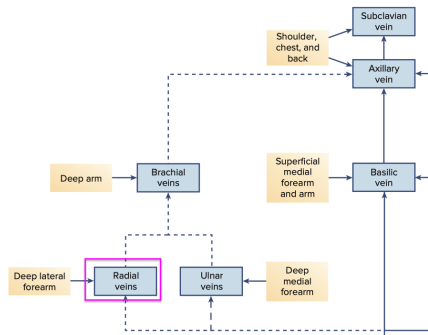


Left Ulnar Vein → Left Brachial Vein → Left Axillary Vein → Left Subclavian Vein → Left Brachiocephalic Vein → Superior Vena Cava





Left Radial Vein

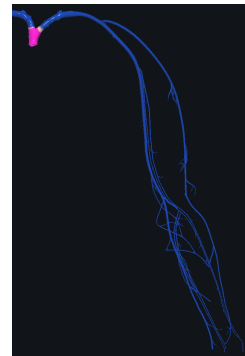
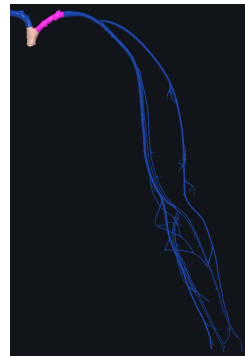
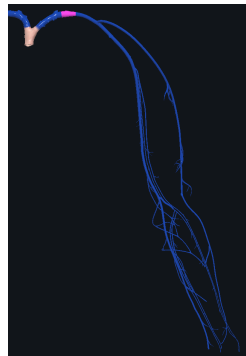
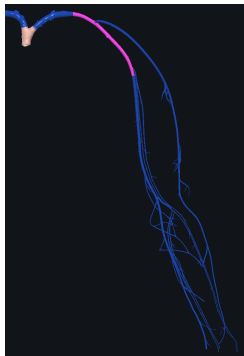
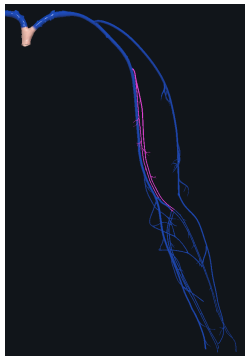
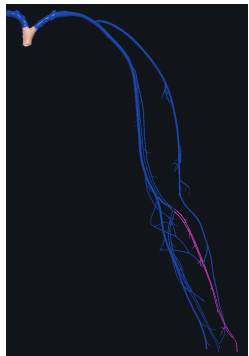
Left Brachial Vein

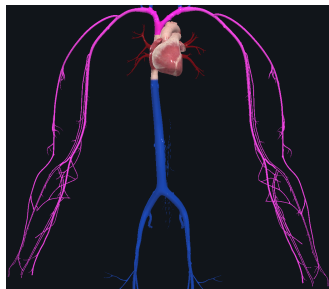
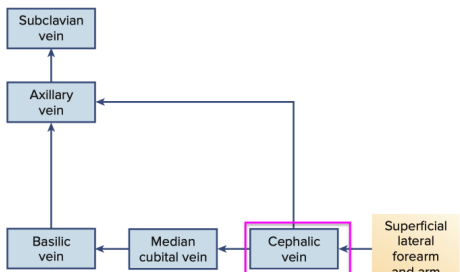
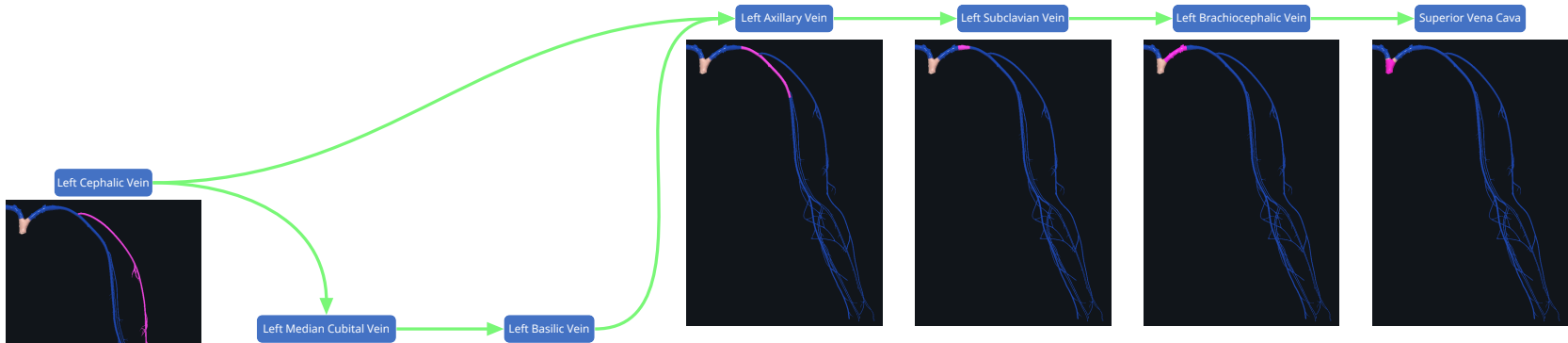
Left Axillary Vein

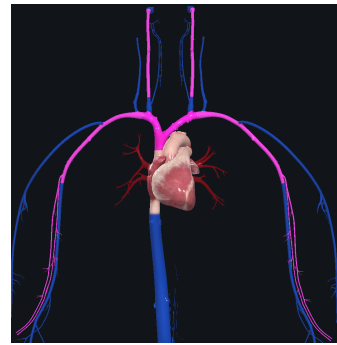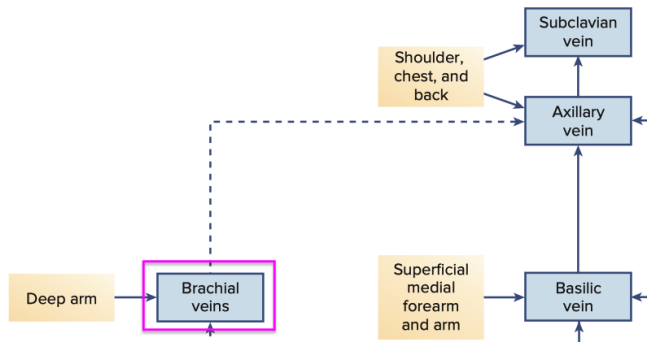
Left Subclavian Vein

Left Brachiocephalic Vein

Superior Vena Cava












Left Brachial Vein

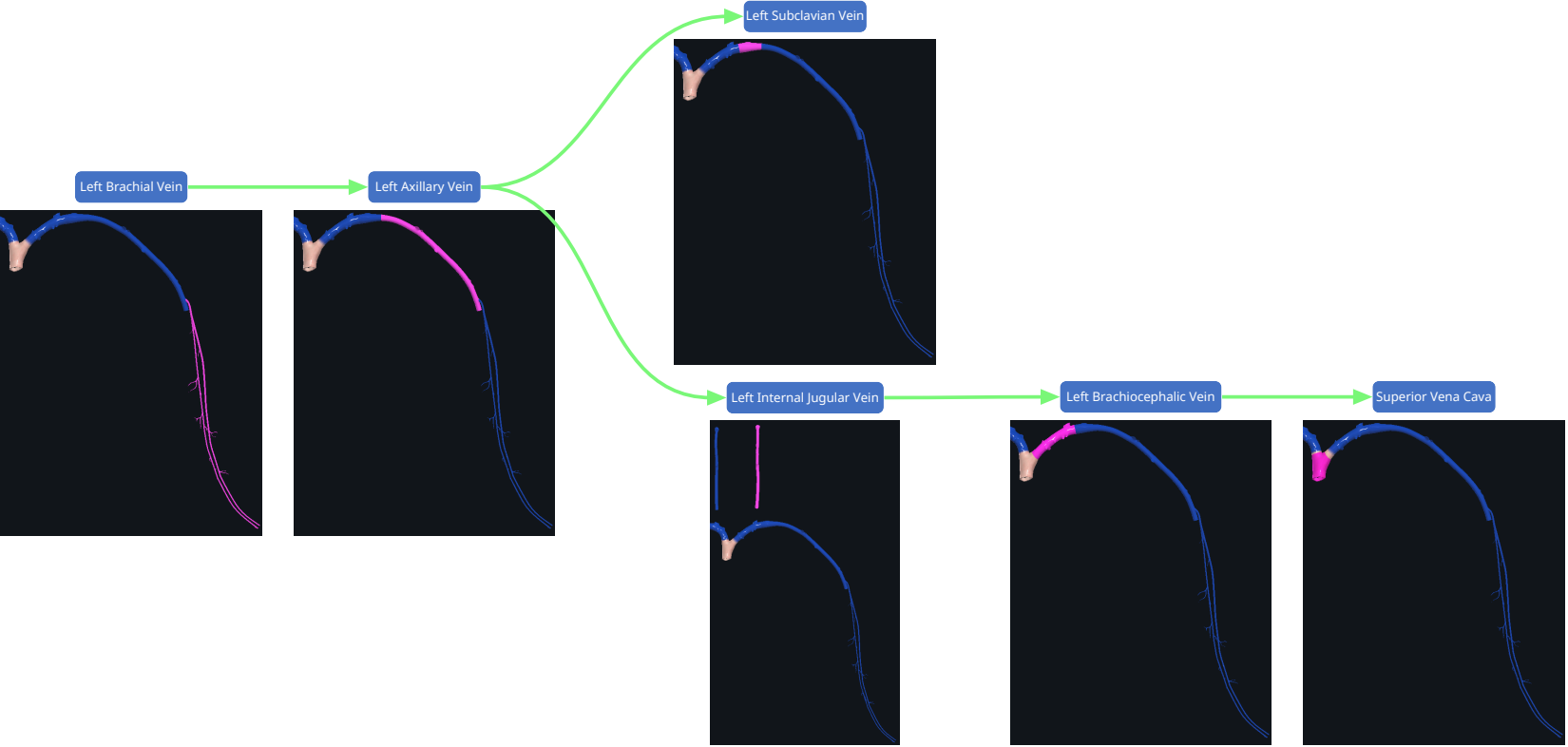
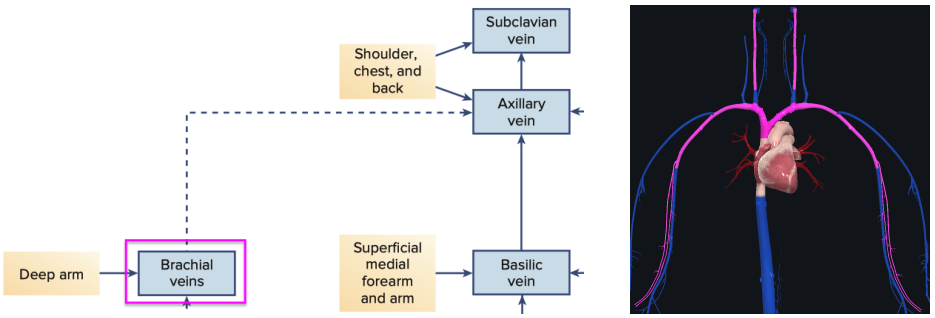
Left Axillary Vein

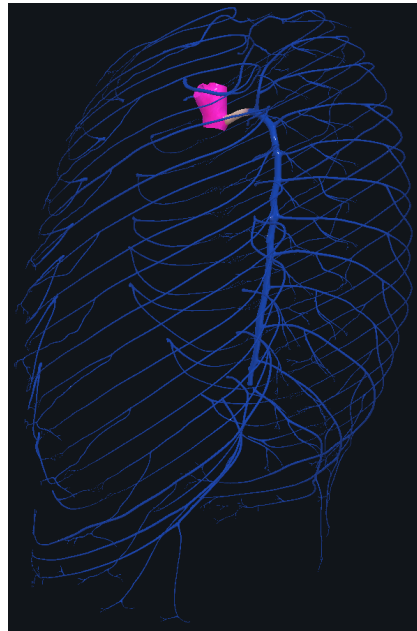
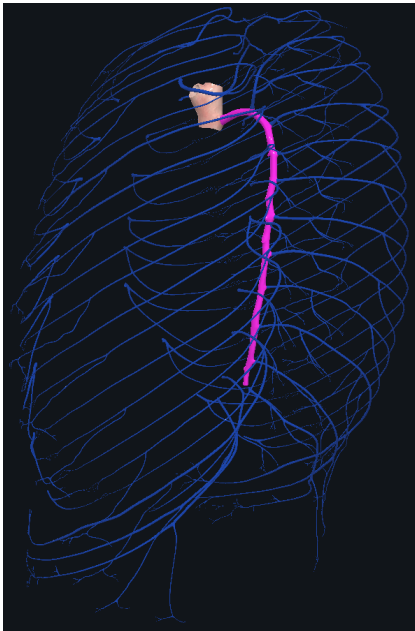
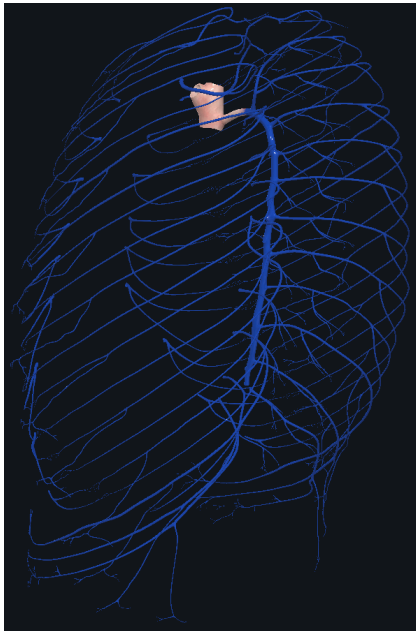
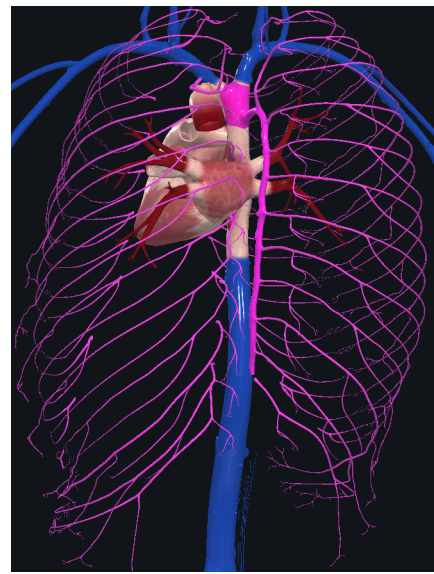
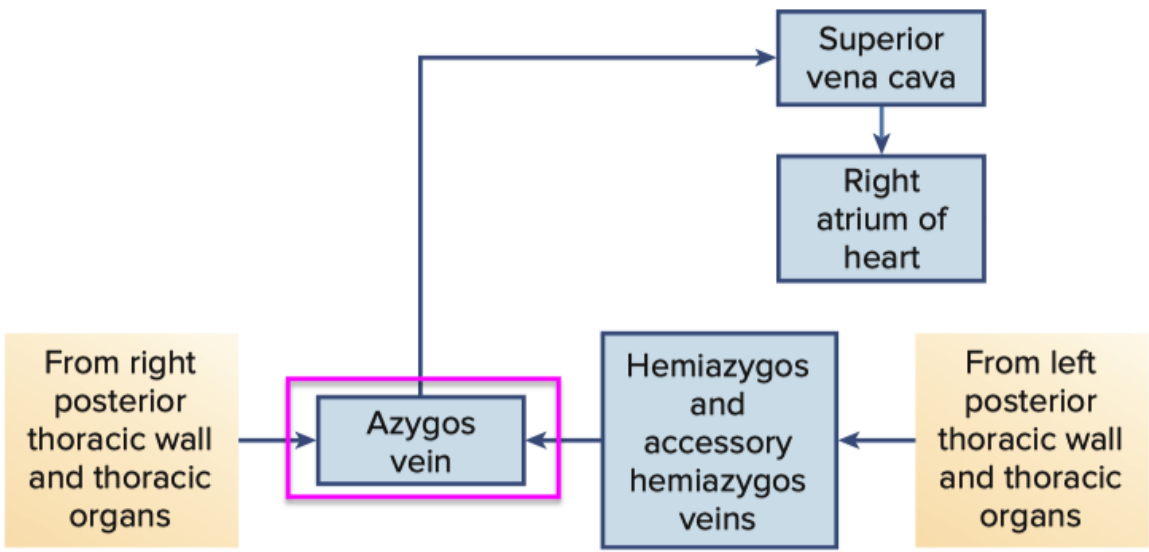
Left Subclavian Vein

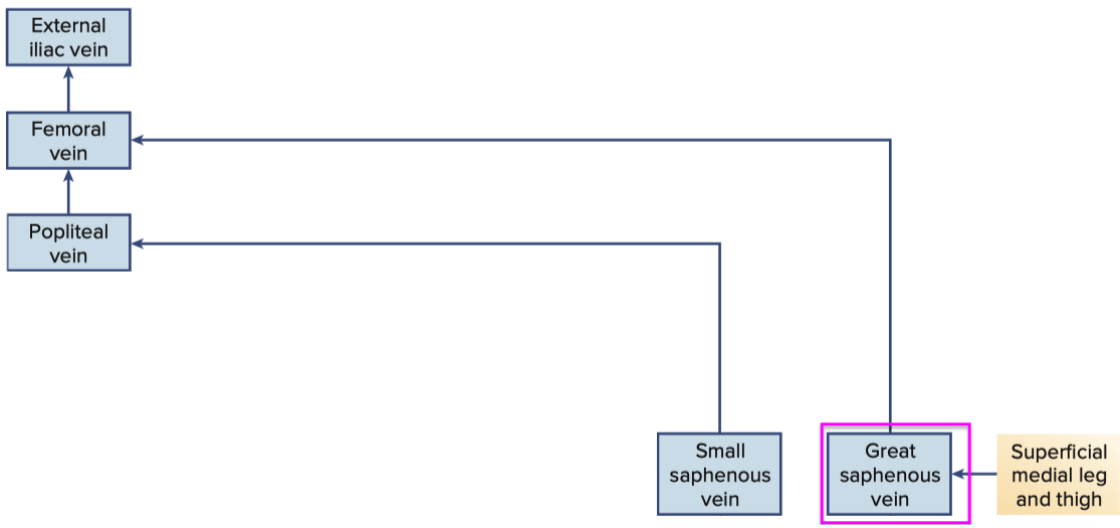
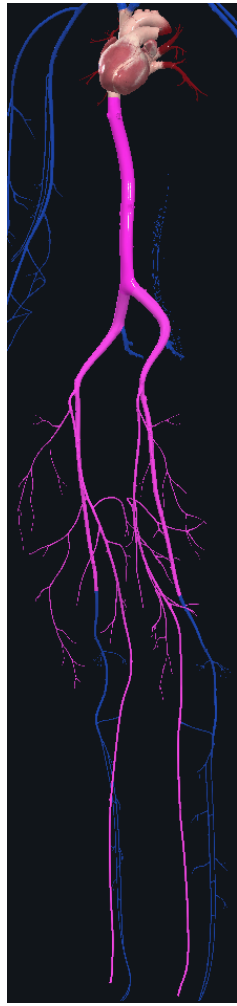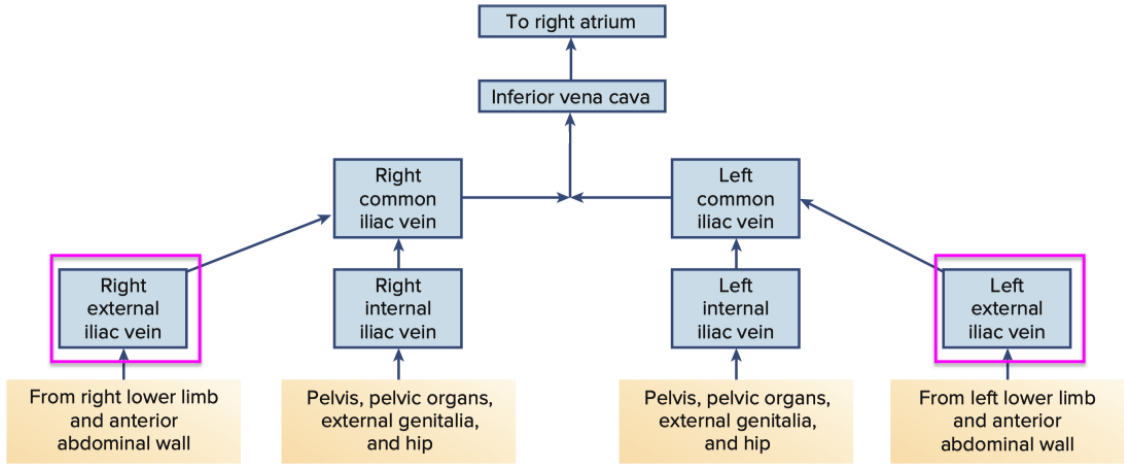
Left Brachiocephalic Vein

Superior Vena Cava


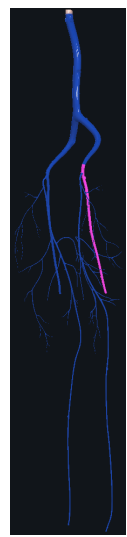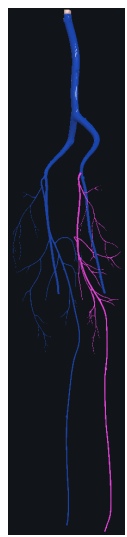


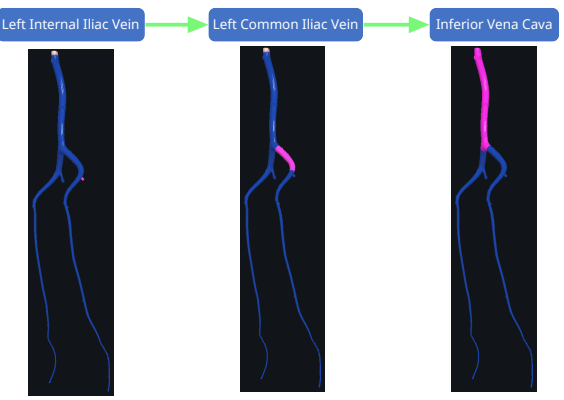
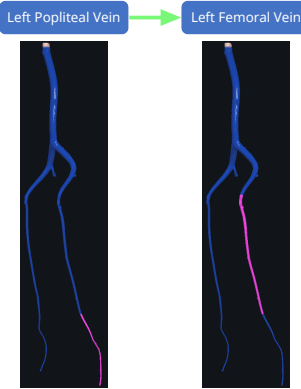
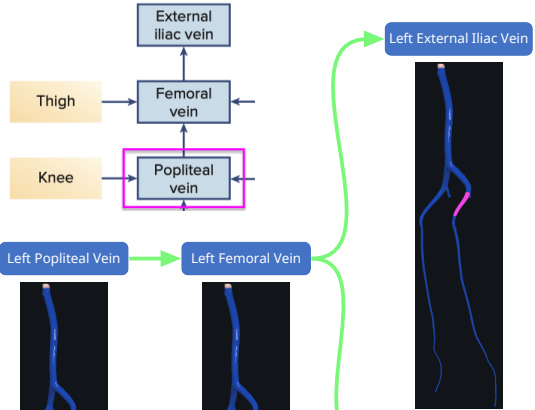
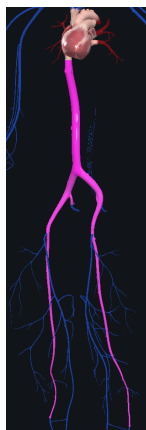
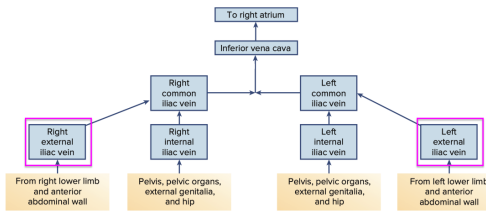




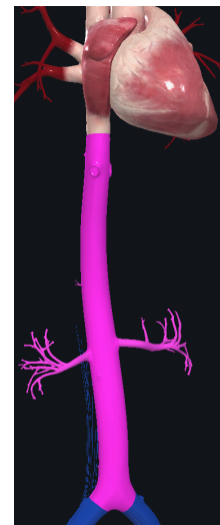
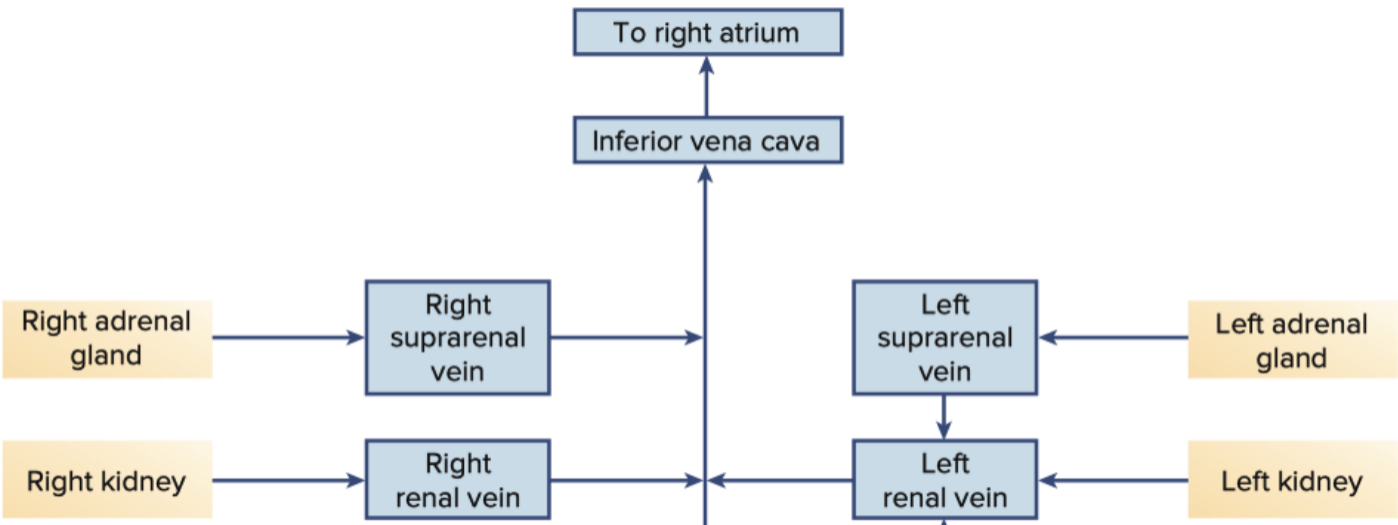


Left Great Saphenous Vein → Left Femoral Vein → Left External Iliac Vein → Left Common Iliac Vein → Inferior Vena Cava

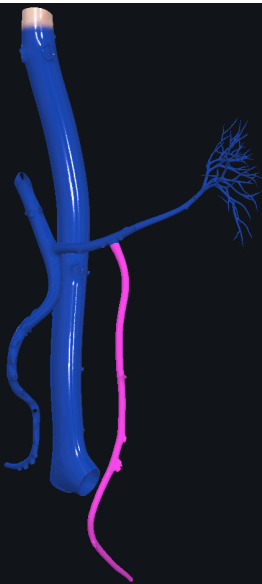




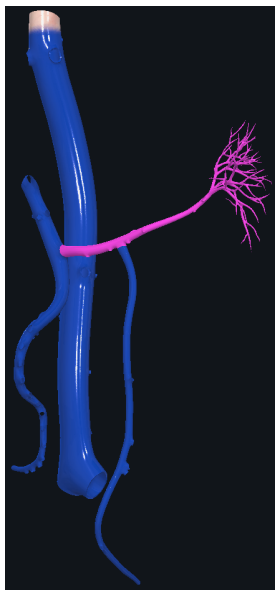




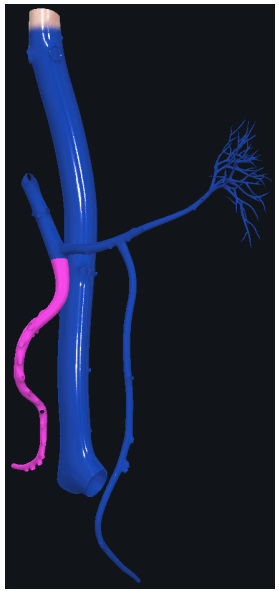
Inferior Mesenteric Vein



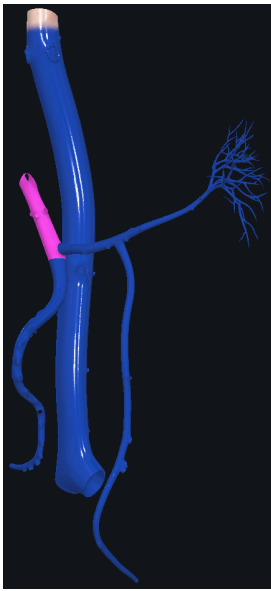
Splenic Vein



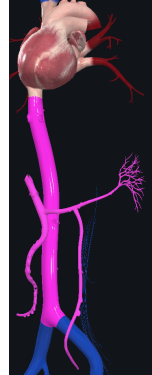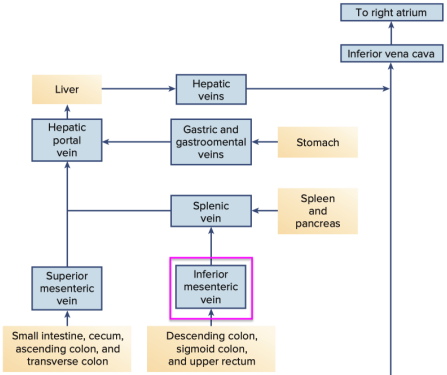
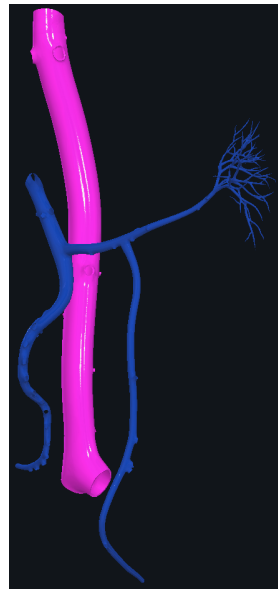
Superior Mesenteric Vein



Hepatic Portal Vein



Inferior Vena Cava



# Venous Sinuses

